

Occurrence of Leporine Psoroptic Mange in Jos Metropolis and Evaluation of Anti-mititic Activities of *Eucalyptus Globulus* and *Azadirachta Indica* oils on Nigerian Hybrid Rabbits

Markus Bukar Biallah*, Longtong Joseph, David Omagbe Oshadu, Paul Davou Kaze and Asabe Cecilia Kogi

Department of Veterinary Parasitology and Entomology, Faculty of Veterinary Medicine, University of Jos, Jos, Nigeria.
Corresponding author email: markusb@unijos.edu.ng; +234 805 2376 240

ABSTRACT:

Rabbits are increasingly recognized as valuable livestock species, yet mange remains a significant ectoparasitic disease affecting dermatological integrity, welfare, and productivity. Ivermectin is the standard therapeutic agent; however, concerns about acaricide resistance, drug residues, and cost necessitate alternative management strategies. This study investigated the prevalence of mange in rabbits within Jos metropolis and evaluated the acaricidal efficacy of *Eucalyptus globulus* and *Azadirachta indica* (Neem) oils. One hundred skin scrapings were collected from rabbits presenting mange-like lesions across multiple farms and examined microscopically for mite identification. Infestation severity was categorised as mild, moderate, or severe. Eight naturally infested rabbits were randomly allocated into four groups (A–D). Group A (positive control) received ivermectin, while Groups B–D were treated topically with *Eucalyptus* oil, Neem oil, or their combination at intervals of 0, 7, 14, 21, and 28 days. Clinical efficacy was assessed based on lesion resolution and recovery rate. Mange prevalence was 79%, with mild (70.9%), moderate (17.7%), and severe (11.4%) infestations showing statistically significant variation ($p < 0.0001$, $\chi^2 = 47.5910$; $df = 2$). Therapeutic response also varied significantly across treatment groups ($p < 0.0001$, $F = 1.844$). *Psoroptes cuniculi* was identified as the predominant mite species. By day 35, *Eucalyptus* oil exhibited superior acaricidal activity, leaving only alopecia, while Neem oil and its combination with *Eucalyptus* produced marked but slightly less rapid healing, with minimal residual crusting. Findings demonstrate a high prevalence of mange in the study area and highlight essential oils as cost-effective, eco-friendly alternatives for rabbit mange control.

Keywords: Rabbit mange, *Psoroptes cuniculi*, *Eucalyptus globulus*, *Azadirachta indica*



Article information
Received 5 June 2025
Accepted 30 July 2025
Published 3 September 2025
<https://doi.org/10.26765/DRJVMAS23445954>

Citation: Biallah, M. B., Joseph, L., Oshadu, D. O., Kaze, P. D., & Kogi, A. C. (2025). Occurrence of Leporine Psoroptic Mange in Jos Metropolis and Evaluation of Anti-mititic Activities of *Eucalyptus Globulus* and *Azadirachta Indica* oils on Nigerian Hybrid Rabbits. Direct Research Journal of Social Science and Educational Studies. Vol. 10(1), Pp. 22-27. This article is published under the terms of the Creative Commons Attribution License 4.0.

INTRODUCTION

Rabbits (*Oryctolagus cuniculus*) are raised globally for various reasons, such as meat production, fur, and scientific study. Despite their prevalence, rabbits are susceptible to multiple skin issues, notably infestations by various mite species, which can significantly impact their health and welfare (Espinosa *et al.*, 2020). Such infestations pose significant challenges in rabbit farming, as they elevate mortality rates, decrease reproductive efficiency, reduce output, and compromise leather quality, thereby endangering economic sustainability. This infectious issue is notoriously resilient, challenging to regulate, and has zoonotic consequences (Kumar *et al.*, 2002). It presents clinically with symptoms like itchiness, hair loss, and prolonged distress, ultimately leading to weight loss and death (Roy *et al.*, 2001). Lesions usually develop on the rabbits' face, neck, and ears. Due to their infectious nature, mites are typically spread among rabbits through environmental contact or direct skin contact between sick and healthy individuals (Panigrahi and Gupta, 2013). Factors like overcrowding and inadequate hygiene significantly contribute to mite infestations (Carthy *et al.*, 2004).

Mites can cause various skin diseases, including demodectic, sarcoptic, psoroptic, and notoedric mange (Kachhawa *et al.*, 2013). Common mite species that affect rabbits include *Psoroptes cuniculi* and *Cheyletiella parasitivorax*, whereas *Sarcoptes scabiei* var. *cuniculi*, *Demodex cuniculi*, and *Notoedres cati* var. *cuniculi* are less prevalent. Moreover, *Trombicula autumnalis* and *Dermanyssus gallinae* can infest rabbits as well.

Mite treatment in rabbits has been successfully achieved through both chemotherapeutic and non-chemotherapeutic approaches (Santos *et al.*, 2017). Common chemotherapeutic options include avermectins such as abamectin, doramectin, ivermectin, and selamectin, along with topical treatments like permethrin, carbamates, benzyl benzoate, and sulfur-based products (Kurtdele *et al.*, 2007). Natural alternatives, including garlic extract, plant essential oils, and non-chemical methods like paraffin oil, have also been explored with varying success against mites (Hanafi *et al.*, 2010). Studies indicate that these oils may work by directly contacting the mites and blocking their airways within the skin, resulting in the suffocation of the parasites (Ellse and Wall, 2014).

This study therefore, seeks to assess the prevalence of mange in rabbits located in Jos, Plateau State, while also evaluating the anti-mititic efficacy of essential oils from *Eucalyptus globulus* (*Eucalyptus*) and *Azadirachta indica* (Neem). It emphasizes their potential effectiveness as agents against mange infestations in Nigerian rabbit breeds and related species.

MATERIALS AND METHODS

Study area

The study was conducted in Jos metropolis. It is located

between latitudes 9° 54' N and 10 ° 10' N and longitudes 8° 48' E and 9° 30' E. The Study area comprises Jos South and Jos North Local Government Areas, with their headquarters in Bukuru and Jos, respectively. The study area, which is situated within the northern senatorial zone of Plateau State, is bounded by Barkin Ladi and Jos East to the east and Bassa Local Government Area to the west.

Study design and sampling

A total of 100 skin scraping samples were collected from rabbits of varying ages and sexes in hutches across Jos metropolis. Each rabbit was examined to assess the presence of mange-like skin lesions. Detailed records were kept regarding the specific body parts that exhibited lesions, including, but not limited to, the ears, body, face, and feet. In this study, clinical assessment scale of grade/level 1, 2 or 3 indicating mild, moderate and severe, were used to determine the severity of the infestation base on severe skin inflammation, pruritus, erythema, and exudation, as well as presence of crusts, flaky scales, scabs, sores, and ulceration of the inner side of the pinnae and on the external ear canal (Eo and Kwon, 2010). Rabbits were meticulously examined for mange-like lesions across several areas of the body, including the head, face, neck, breast, brisket, ears, feet, and tail. Skin scrapings were collected only from those individuals exhibiting clear signs of mange. The samples were then promptly transported to the Entomology Teaching and Research Laboratory, the Faculty of Veterinary Medicine, University of Jos, for further diagnostic analysis.

Laboratory analysis of skin scrapings

The laboratory analysis involved placing a portion of the skin scrapings into test tubes containing 5 mL of 10% potassium hydroxide (KOH) solution. These tubes were subjected to a water bath at temperatures ranging from 60-80°C for 15 minutes to facilitate the dissolution of skin debris. These samples were then centrifuged at a speed of 1500-2000 revolutions per minute for 5 minutes. The supernatant was discarded using an automatic pipette, and the sediments were thoroughly mixed. Aliquots from this mixture were pipetted onto a grease-free microscope slide on which cover slips were placed. Permanent mounts of mites on the slides were prepared following the standard laboratory procedures. Species determination of the mites was performed based on their morphological characteristics (Mathison *et al.*, 2014).

Evaluation of essential oils against mange

The rabbits with mange-like lesions were separated into four groups (A-D) of 2 each (n=2) and given treatment as seen in (Table 1). Neem oil (*Azadirachta indica*) and *Eucalyptus* oil (*Eucalyptus globulus*) were 100% pure oils. For each oil treatment, 2 mL of oil was applied topically to the affected body area of the infested rabbits (B-D) on days

Table 1: Experimental design on the anti-ectoparasitic evaluation of essential oils.

Groups	A	B	C	D (mixture)
Products	Ivermectin (IV) Positive control	<i>Eucalyptus</i> oil (EU)	Neem oil (NM)	EU + NM (1:1)

Table 2: Prevalence of mange in Jos metropolis.

Samples	Number	Percentage (%)
Positive	79	79
Negative	21	21
Total	100	100

Table 3: The severity of mite infestation in Jos metropolis.

Severity	Number of infested rabbits	Infestation rate (%)
Mild	56	70.9
Moderate	14	17.7
Severe	9	11.4
Total	79	100

$\chi^2=47.5910$; $df=2$; $p<0.0001$

0, 7, 14, 21, and 28th. Subcutaneous Ivermectin injections were given on the scruff of the rabbits of Group A for the four-week study period as the control (positive) group.

Statistical analysis

The data generated was expressed in tables and figures using Excel in Microsoft Office 2019. Analysis for variation was carried out using Chi-square for the distribution of variation in frequency of occurrence of the level of severity of mange, and Analysis of Variance (ANOVA) for variation in the healing effect of the various treatment groups. Variations with $p<0.05$ were considered statistically significant at a 95% confidence interval in JMP version 17.

RESULTS AND DISCUSSION

The prevalence of mange documented in this study indicates that the incidence among rabbits in the Jos metropolis is significantly high (Table 2). This is consistent with the findings of Ola-Fadunsin *et al.* (2018) in Osun State, Nigeria, and Chebet *et al.* (2018) in Kenya, where they reported prevalence of 70.27% and 57.3%, respectively. However, it differs from the findings of Khalil *et al.* (2024) in Iraq, who reported an overall prevalence of 23.6%. These similarities and differences can be attributed to the varying environmental conditions of the various study locations. Jos is attributed with a reduced temperature and elevated humidity, most especially in the rainy season, during which this study was conducted. Other factors could be the housing system and practices, as was observed during the sample collection of this study, where some of the animals were found on the bare floor and with cages or pens not cleaned, allowing room for their fur to remain wet. This predisposes to infestation with ectoparasitism, including mite infestation (Chebet *et al.*, 2018).

The species responsible for the prevalence of mange

identified in this study was *Psoroptes cuniculi*, which is one of the most commonly reported causes of mange in rabbits. Although there are few research works done in Nigeria referencing the cause of mange in rabbits, research carried out in other countries like Kenya by Chebet *et al.* (2018) reported *Psoroptes cuniculi* as the major cause of mange in rabbits, while in Iraq, Khalil *et al.* (2024) reported *Psoroptes cuniculi* as the second major cause of mange in rabbits, with *Sarcoptes scabiei* var. *cuniculi* being the first. The occurrence of *Psoroptes cuniculi* as the sole cause of mange in this study can be due to the poor hygienic practices in the farms visited as well as the breed as the majority of the breed in Jos is the Flemish giant which was reported by Chebet *et al.* (2018) to be the most susceptible to infestation by *Psoroptes cuniculi* in Kenya. Also, the climatic conditions of Jos could be another factor for which *Psoroptes cuniculi* was the only mite, as Liu *et al.* (2017) noted that *Psoroptes cuniculi* flourishes in cooler and more humid environments.

The severity of most of the mange cases sampled in this study being mild (Table 3) is indicative of a recent infestation as well as a pointer to an enhanced awareness among rabbit farmers regarding optimal hygiene practices, appropriate housing, and stocking density in rabbit husbandry, which are critical factors influencing mite infestations, as observed by Carthy *et al.* (2004). However, the 11.4% severe level of infestation is a pointer to the need for improvement in the breeding practices among some farmers.

The high number of lesions observed in this study, as well as their spread on various parts of the animal body, suggests that *Psoroptes cuniculi* infestation has no predilection site and its ability to cause various irritations to the animal, resulting in the various lesions manifesting. The results of this study provide valuable insights into the efficacy of various treatments for lesions associated with mange, a condition commonly affecting animals. A total of 11 lesions were evaluated at the onset of treatment, all categorized as mild. The findings indicate that the

Table 4: Treatment of mange-infested rabbits with *Eucalyptus* oil.

Lesion	Day 0		Day 14		Day 28		Day 35	
	IV	EU	IV	EU	IV	EU	IV	EU
Intense pruritus	+	+	-	-	-	-	-	-
Head shaking	+	+	-	-	-	-	-	-
Erythema	+	+	-	-	-	-	-	-
Crust, scales, and scabs on the inner side of the pinnae	+	+	+/-	+	-	+/-	-	-
Crust, scales, and scabs on the external canal	+	+	+/-	+	-	+/-	-	-
Crust, scales, and scabs on the body	+	+	-	+/-	-	-	-	-
Drooping ears	+	+	-	+	-	+/-	-	-
Foul-smelling discharge from the external ear canal	+	+	+/-	+	-	+/-	-	-
Pain on palpation of the ears	+	+	-	-	-	-	-	-
Alopecia	+	+	+/-	+	-	+/-	-	+/-
Ulceration	+	+	-	+	-	+/-	-	-

IV=Ivermectin; EU=*Eucalyptus* oil; + lesion present; - lesion absent; +/- lesion partially present

Table 5: Treatment of mange-infested rabbits with Neem oil.

Lesion	Day 0		Day 14		Day 28		Day 35	
	IV	NM	IV	NM	IV	NM	IV	NM
Intense pruritus	+	+	-	-	-	-	-	-
Head shaking	+	+	-	+	-	-	-	-
Erythema	+	+	-	+	-	-	-	-
Crust, scales, and scabs on the inner side of the pinnae	+	+	+/-	+	-	+/-	-	+/-
Crust, scales, and scabs on the external canal	+	+	+/-	+	-	+/-	-	-
Crust, scales, and scabs on the body	+	+	-	-	-	-	-	-
Drooping ears	+	+	-	+	-	+/-	-	-
Foul-smelling discharge from the external ear canal	+	+	+/-	+	-	+/-	-	-
Pain on palpation of the ears	+	+	-	-	-	+/-	-	-
Alopecia	+	+	+/-	+	-	+/-	-	+/-
Ulceration	+	+	-	+	-	+/-	-	-

IV=Ivermectin; EU=*Eucalyptus* oil; + lesion present; - lesion absent; +/- lesion partially present

Table 6: Treatment of mange-infested rabbits with a mixture of *Eucalyptus* and Neem oils.

Lesion	Day 0		Day 14		Day 28		Day 35	
	IV	Mix	IV	Mix	IV	Mix	IV	Mix
Intense pruritus	+	+	-	-	-	-	-	-
Head shaking	+	+	-	+	-	-	-	-
Erythema	+	+	-	+	-	-	-	-
Crust, scales, and scabs on the inner side of the pinnae	+	+	+/-	+	-	+/-	-	+/-
Crust, scales, and scabs on the external canal	+	+	+/-	+	-	+/-	-	-
Crust, scales, and scabs on the body	+	+	-	+/-	-	+/-	-	-
Drooping ears	+	+	-	+	-	+/-	-	-
Foul-smelling discharge from the external ear canal	+	+	+/-	+	-	+/-	-	-
Pain on palpation of the ears	+	+	-	-	-	-	-	-
Alopecia	+	+	+/-	+	-	+/-	-	+/-
Ulceration	+	+	-	+	-	+/-	-	-

IV=Ivermectin; Mix=*Eucalyptus* and Neem oils (1:1); + lesion present; - lesion absent; +/- lesion partially present

treatment strategies evaluated *Eucalyptus* oil, Neem oil, a combination of both, and the control group treated with ivermectin exhibit varied levels of success in healing these lesions over the study period (Table 7 and Figure 1). At the two-week mark, the *Eucalyptus* oil group demonstrated the most significant healing effect, with four lesions completely healed. This suggests that *Eucalyptus* oil may possess strong therapeutic properties, potentially due to its anti-inflammatory and antimicrobial characteristics (Catarino *et al.*, 2020). In contrast, the combination of *Eucalyptus* and Neem oils yielded the least effective results, with only two lesions resolved (Tables 6 and 7, and Figure 1). This finding highlights an intriguing interaction between the oils, which warrants further investigation to understand the underlying mechanisms of their actions as an entity or in combination (Khan *et al.*, 2021). Neem oil alone was

moderately effective, achieving complete healing in three lesions, which aligns with existing literature that suggests antimicrobial effects of Neem oil (Gita *et al.*, 2018). The control group treated with ivermectin also showed promising results, with all lesions demonstrating signs of healing by day 28, ultimately resulting in complete resolution by day 35 (Tables 4-7 and Figure 1). This aligns with the established efficacy of ivermectin in treating parasitic conditions (Failoc-Rojas *et al.*, 2023). However, it is pertinent to note that while the control treatment was effective, it is a synthetic pharmaceutical, which raises considerations regarding its long-term use and potential side effects in veterinary practices (Zhou *et al.*, 2022). The data collected at 28 days post-treatment further emphasise a significant improvement across all treatment groups. While *Eucalyptus* oil had six lesions partially

Table 7: Treatment of mange in rabbits with *Eucalyptus*, Neem oil, mixture, and Ivermectin.

Lesion	Day 0				Day 14				Day 28				Day 35			
	IV	EU	NM	Mix	IV	EU	NM	Mix	IV	EU	NM	Mix	IV	EU	NM	Mix
Intense pruritus	+	+	+	+	-	-	-	-	-	-	-	-	-	-	-	-
Head shaking	+	+	+	+	-	-	+	+	-	-	-	-	-	-	-	-
Erythema	+	+	+	+	-	-	+	+	-	-	-	-	-	-	-	-
Crust, scales, and scabs on the inner side of the pinnae	+	+	+	+	+/-	+	+	+	-	+/-	+/-	+/-	-	-	+/-	+/-
Crust, scales, and scabs on the external canal	+	+	+	+	+/-	+	+	+	-	+/-	+/-	+/-	-	-	-	-
Crust, scales, and scabs on the body	+	+	+	+	-	+/-	-	+/-	-	-	-	+/-	-	-	-	-
Drooping ears	+	+	+	+	-	+	+	+	-	+/-	+/-	+/-	-	-	-	-
Foul-smelling discharge from the external ear canal	+	+	+	+	+/-	+	+	+	-	+/-	+/-	+/-	-	-	-	-
Pain on palpation of the ears	+	+	+	+	-	-	-	-	-	-	+/-	-	-	-	-	-
Alopecia	+	+	+	+	+/-	+	+	+	-	+/-	+/-	+/-	-	+/-	+/-	+/-
Ulceration	+	+	+	+	-	+	+	+	-	+/-	+/-	+/-	-	-	-	-

IV – Ivermectin, EU – Eucalyptus oil, NM – Neem oil, Mix – Eucalyptus and Neem oil (1:1); + lesion present; - lesion absent; +/- lesion partially present

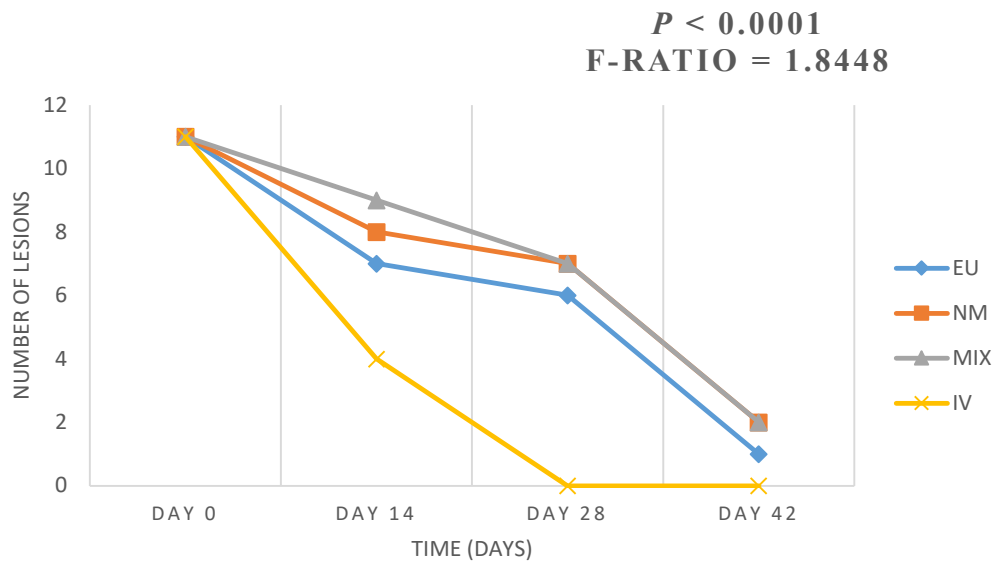


Figure 1: Overall healing effect of *Eucalyptus* and Neem oil

present, both the Neem oil and its combination with *Eucalyptus* oil groups had seven lesions partially healed. These results suggest that while *Eucalyptus* oil may initially demonstrate a stronger effect, the other treatments caught up in the later stages, indicating a gradual healing process influenced by the properties of each treatment (Patel *et al.*, 2019). By day 35, most lesions had resolved; however, *Eucalyptus* oil-treated animals still presented with partial alopecia, while Neem oil and its combination with *Eucalyptus* oil exhibited ongoing issues with crust, scales, and scabs, in addition to alopecia (Table 7). This residual presence of symptoms suggests that while the oils could effectively promote initial healing, additional treatments or longer durations may be necessary to achieve full recovery without residual effects (Singh *et al.*, 2019).

Conclusion

This study elucidates the prevalence of mange in rabbits and the comparative efficacy of *Eucalyptus* oil, Neem oil, a combination of both, and ivermectin (positive control) in treating the lesions associated with mange in affected animals. The findings reveal a high prevalence of mange in Jos metropolis, although the majority of the cases are observed to be mild. The species of mange implicated in this research is *Psoroptes cuniculi*. In treatment, *Eucalyptus* oil exhibited superior initial healing effects, probably due to its potent anti-inflammatory and antimicrobial properties. Neem oil also showed promise, achieving significant healing results on its own and in combination with *Eucalyptus* oil, providing further evidence of its therapeutic potential. While the mixture did not

outperform *Eucalyptus* oil alone, it nonetheless highlights the complexity of herbal interactions, warranting deeper investigation into how these natural compounds can be best utilized together for enhanced therapeutic outcomes. Besides the practice of hygiene, culling of infested animals and biosecurity in hutches, it is therefore recommended that the use of essential oils of *Eucalyptus globulus* and *Azadirachta indica* (Neem) be explored in the management of mange in rabbits as an alternative strategy that is cost-effective and ecosystem-friendly.

Conflict of Interest

The authors declare that they do not have a conflict of interest.

REFERENCES

- Carthy, J. S. M., Kemp, D. J., Walton, S. F., & Currie, B. J. (2004). Scabies: more than just an irritation. *Postgraduate Medical Journal*, 80, 382-387. <https://doi.org/10.1136/pgmj.2003.014563>
- Catarino, J. M., Figueiredo, A. C., & Ferreira, E. A. (2020). *Eucalyptus* essential oil: Sources, chemical composition, and antimicrobial activity. *Plants*, 9(5), 546. <https://doi.org/10.3390/plants9050546>
- Chebet, J., Waruiru, R. M., Ogola, K. O., Gathumbi, P. K., Okumu, P. O., Wanyoike, M., & Aboge, G. O. (2018). Prevalence, control, and risk factors associated with rabbit mange in Kiambu and Nyeri counties, Kenya. *Livestock Research for Rural Development*, 30, 108. Retrieved February 25, 2025, from <http://www.lrrd.org/lrrd30/6/rmwa30108.html>
- Ellse L, & Wall R. (2014). The use of essential oils in veterinary ectoparasite control: a review. *Medical and Veterinary Entomology*, 28(3), 233-243. doi: 10.1111/mve.12033. Epub 2013 Oct 22. PMID: 24147451.
- Eo, K.-Y. & Kwon, O.-D. (2010). Psoroptic Otocariasis Associated with *Psoroptes cuniculi* in Domestic Rabbits in Korea. *Pakistan Veterinary Journal*, 30, 251-252.
- Espinosa, J., Pérez, J. M., Baéz-Bravo, A., Fandos, P., Cano-Manuel, F. J., Soriguer, R. C., López-Olvera, J. R., & Granados, J. E. (2020). Recommendations for the management of sarcoptic mange in free-ranging Iberian ibex populations. *Animal Biodiversity and Conservation*, 43, 137-149. <https://doi.org/10.32800/abc.2020.43.013>
- Failoc-Rojas, V. E., Silva-Díaz, H., Maguiña, J. L., Rodríguez-Morales, A. J., Díaz-Velez, C., Apolaya-Segura, M., & Valladares-Garrido, M. J. (2023). Evidence-based indications for ivermectin in parasitic diseases: An integrated approach to context and challenges in Peru. *Parasite Epidemiology and Control*, 23, e00320. <https://doi.org/10.1016/j.parepi.2023.e00320>
- Gita, M., Afreen, S., & Ahsan, M. (2018). The healing properties of neem: A review. *International Journal of Green Pharmacy*, 12(2), 178-185. <https://doi.org/10.22377/ijgp.v12i2.2196>
- Hanafi, E., Maghraby, N., Ramadan, M., & El-Allawy, H. (2010). Aromatherapy of *Cinnamomum zeylanicum* bark oil for treatment of scabies in rabbits with emphasis on productive performance. *American-Eurasian Journal of Agriculture and Environmental Science*, 7(6), 719-727.
- Kachhawa, J. P., S. Lachhawa, M. Srivastava, A. Chahar, and Singh, N. K. Therapeutic Management in Rabbits. *Intas Polivet* 14 (2013): 306-08.
- Khan, T. N. S., Mukry, S. N., Masood, S., Meraj, L., Devrajani, B. R., Akram, J., Fatima, N., Maqsood, S., Mahesar, A., Siddiqui, R., Ishaque, S., Afzal, M. B., Mukhtar, S., Ahmed, S., Naz, A., & Shamsi, T. S. (2021). Usefulness of convalescent plasma transfusion for the treatment of severely ill COVID-19 patients in Pakistan. *BMC infectious diseases*, 21(1), 1014. <https://doi.org/10.1186/s12879-021-06451-7>
- Kumar, P., Sahay, M. N., Sinha, V. K., & Samantaray, S. (2002). Comparative efficacy of some acaricides against mange in dogs. *Indian Veterinary Journal*, 79, 828-830.
- Kurtdele, A., Karaer, Z., Acar, A., Guzel, M., Cingi, C. C., Uralm, K., Ica, A. (2007). Use of selamectin for the treatment of psoroptic and sarcoptic mite infestation in rabbits. *Veterinary Dermatology*, 18(1), 18-22. doi: 10.1111/j.1365-3164.2007.00563.x. PMID: 1722235.
- Liu, Y., Wang, W., Li, X., Zhang, Y., & Chen, J. (2017). Effects of temperature on the development and reproduction of *Psoroptes cuniculi*. *Veterinary Parasitology*, 238, 43-48. <https://doi.org/10.1016/j.vetpar.2017.03.005>
- Mathison, B. A., & Pritt, B. S. (2014). Laboratory identification of arthropod ectoparasites. *Clinical microbiology reviews*, 27(1), 48-67. <https://doi.org/10.1128/CMR.00008-13>
- Niaz, K., & Shoaib, M. (2015). Comparative study of ivermectin and cypermethrin against *Sarcoptes scabiei* in rabbits. *International Journal of Innovative Research and Development*, 4(5), 2015.
- Ola-Fadunsin, S. D., Hussain, K., Rabi, M., & Ganiyu, I. A. (2018). Parasitic conditions of domestically owned rabbits in Osun State, southwestern Nigeria: Retrospective evaluation, risk factors, and co-infestations. *International Journal of Veterinary Science and Medicine*, 6(2), 208-212. <https://doi.org/10.1016/j.ijvsm.2018.06.002>
- Panigrahi, P. N., & Gupta, A. R. (2013). Therapeutic management of concurrent sarcoptic and Psoroptic acariasis in rabbits. *IntasPolivet*, 14(11), 319-321.
- Patel, D., Bhavsar, P., & Patel, M. (2019). Evaluation of wound healing potential of *Eucalyptus citriodora* on experimental model. *International Journal of Pharmacognosy and Phytochemical Research*, 11(1), 13-18. <https://www.ijpsr.com/index.php/home/article/view/4823>
- Roy, S., Roy, M., Dutta, G. K., Pal, S., & Tiwari, S. K. (2001). Therapeutic evaluation of herbal preparations against demodectic mange infection in dogs. *Indian Veterinary Journal*, 78, 629-630.
- Santos R. R., Coelho C. N., Nunes T. A. P., Batista, L. C., de, S. O., Correia, T. R., Scott, F. B., Laguna, A. G. V. & Fernandes, J. I. (2017). Efficacy of oral doramectin as treatment for *Psoroptes ovis* and *Leporacarus gibbus* in naturally infested rabbits. *Pesquisa Veterinária Brasileira*, 37(1), 47-51. <https://doi.org/10.1590/S0100-736X2017000100008>